

Differential Diagnosis of Knee Pain

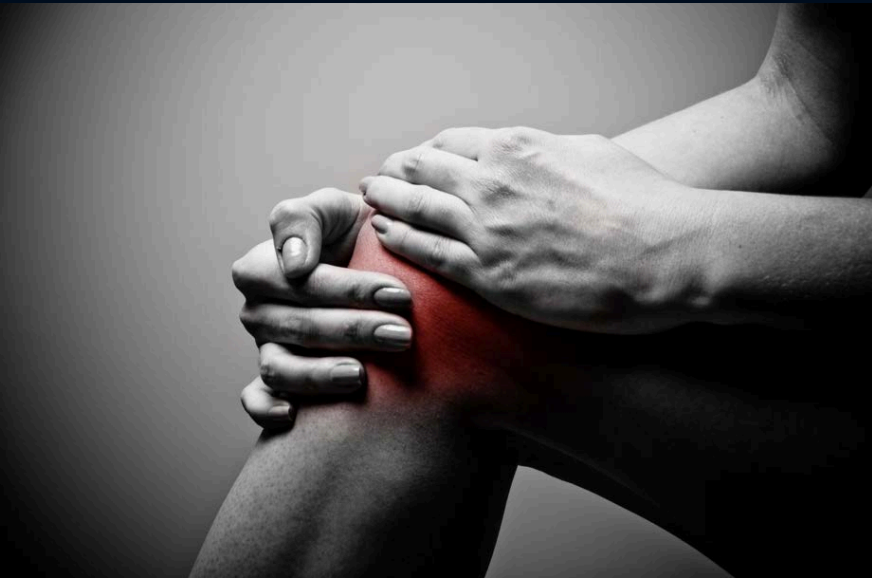November 11, 2016

Raymond H. Kim, M.D.


**Colorado Joint Replacement
Porter Adventist Hospital
Denver, Colorado**

**Adjunct Associate Professor of Bioengineering,
Department of Mechanical and Materials
Engineering, University of Denver**


**Clinical Associate Professor
Department of Orthopaedic Surgery
Joan C. Edwards School of Medicine
at Marshall University**



Disclosures




- **Consulting: DJO Surgical**
- **Product Development: DJO Surgical**
- **Speaker bureau: Convatec**
- **Speaker bureau: Ceramtec**
- **Research support: Porter Adventist Hospital**
- **Royalties: Innomed**




- **Evaluation of knee pain**
- **Differential diagnosis**
- **Specific knee conditions**

Evaluation of Knee Pain

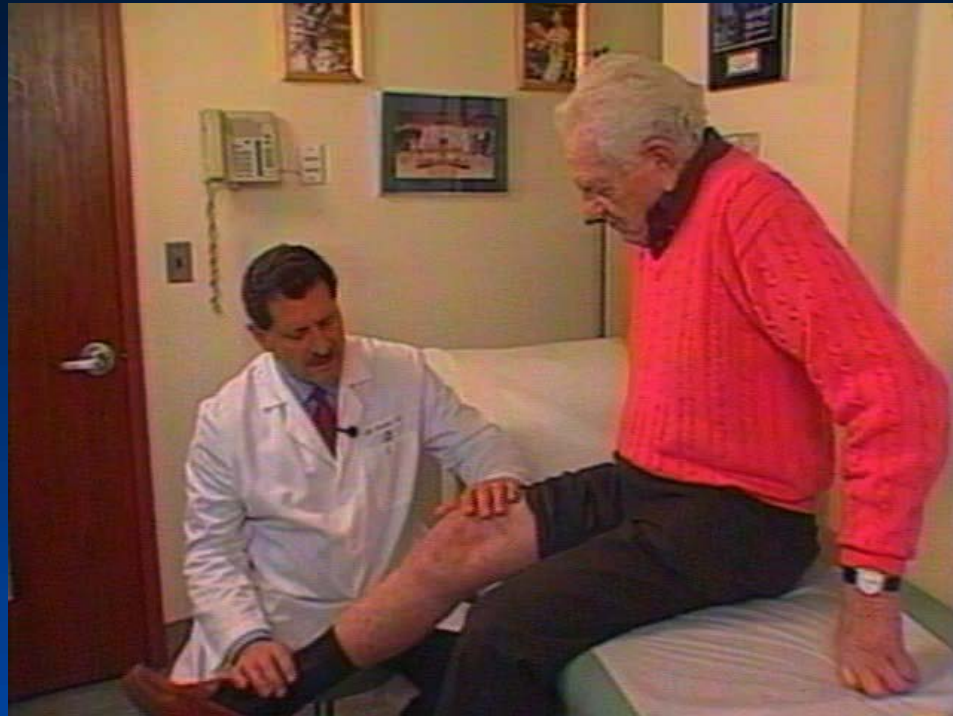

- **Meticulous gathering of patient history**
- **Thorough physical exam**
- **Imaging studies**
- **Possible laboratory studies**
- **Possible arthrocentesis**


Most Diagnoses Can Be Made With:



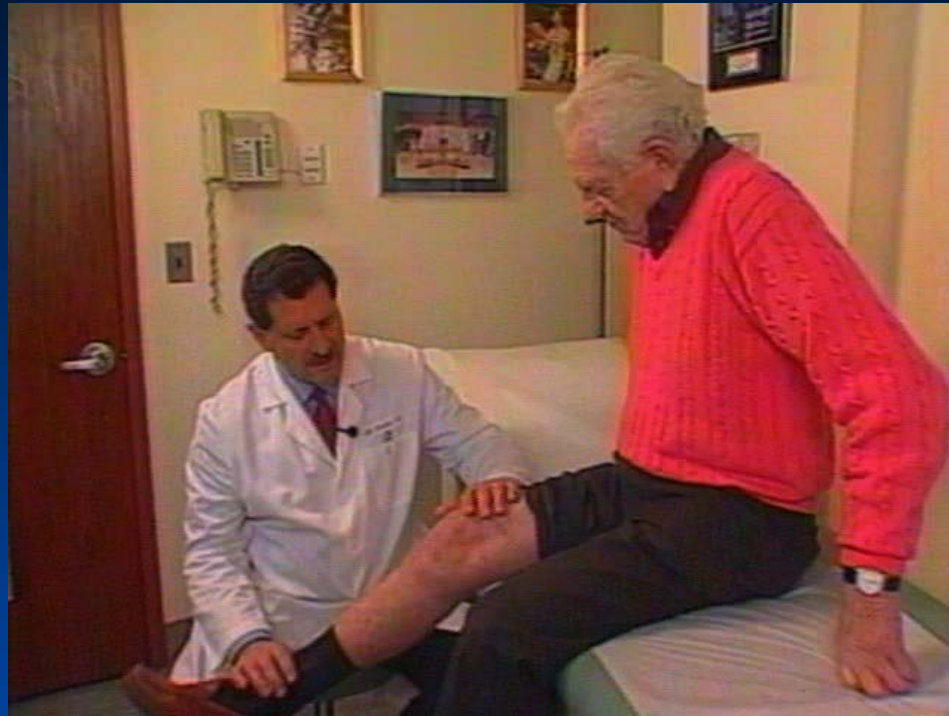- History
- Physical exam
- Plain radiographs




History



- Age, gender
- Duration of pain
- Location
- Quality
- Alleviating factors
- Exacerbating factors
- History of trauma
- Locking, catching, swelling
- Weight-bearing pain
- Night pain




History



- **PMH**
 - Previous surgery?
- **Meds**
 - Steroids? NSAIDs?
- **Social hx**
 - EtOH? Smoking?
- **Family hx**
 - Rheumatologic conditions?
- **ROS**




Physical Exam



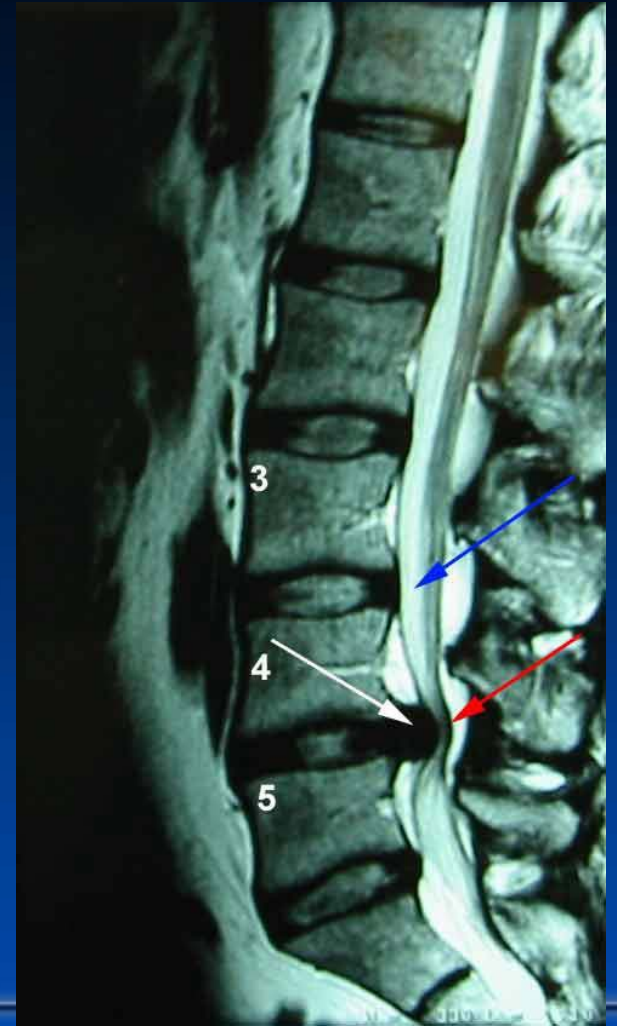
- Spine
- Hip
- Knee




Spine Exam is Part of the Knee Exam!



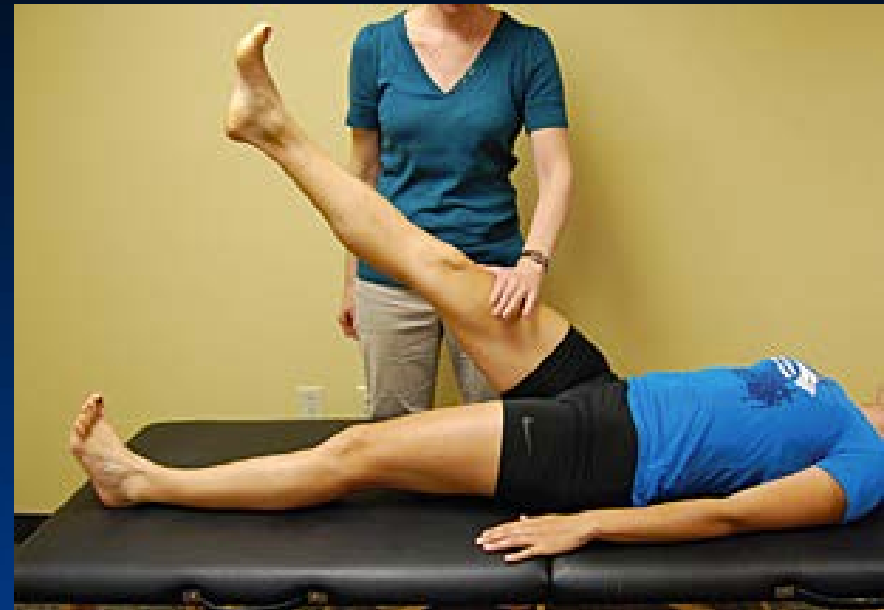- Physical examination of the lumbar spine
- Unexplained “knee” pain
- Referred pain from lumbar radiculopathy
- Spinal stenosis




Hip Exam is Part of the Knee Exam!



- Physical examination of the hip
- Referred pain from the hip
- Hip arthritis
- Failed THA

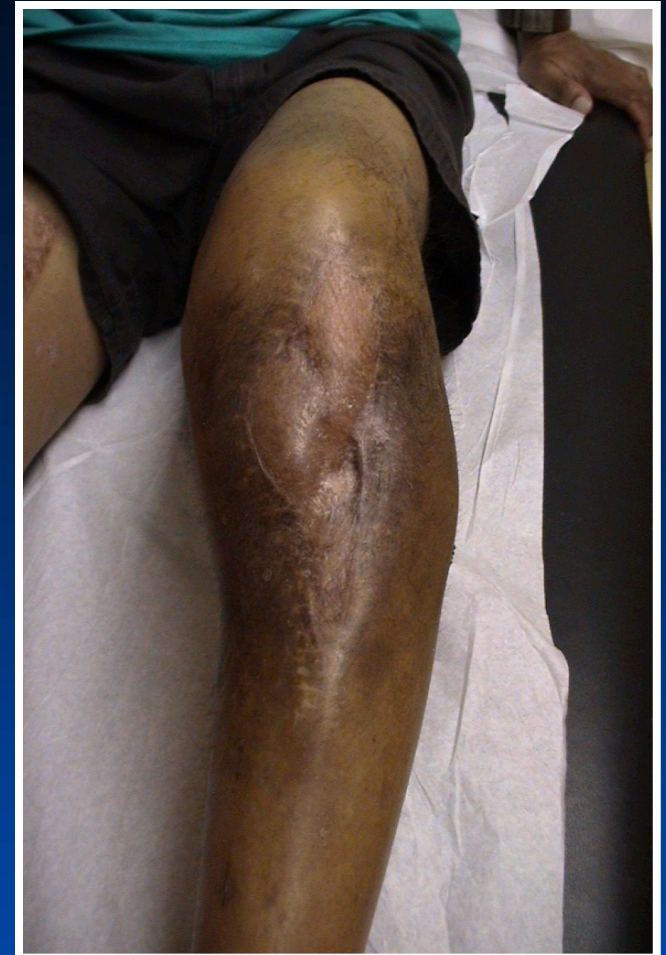

Physical Examination of the Knee




- **Observation**

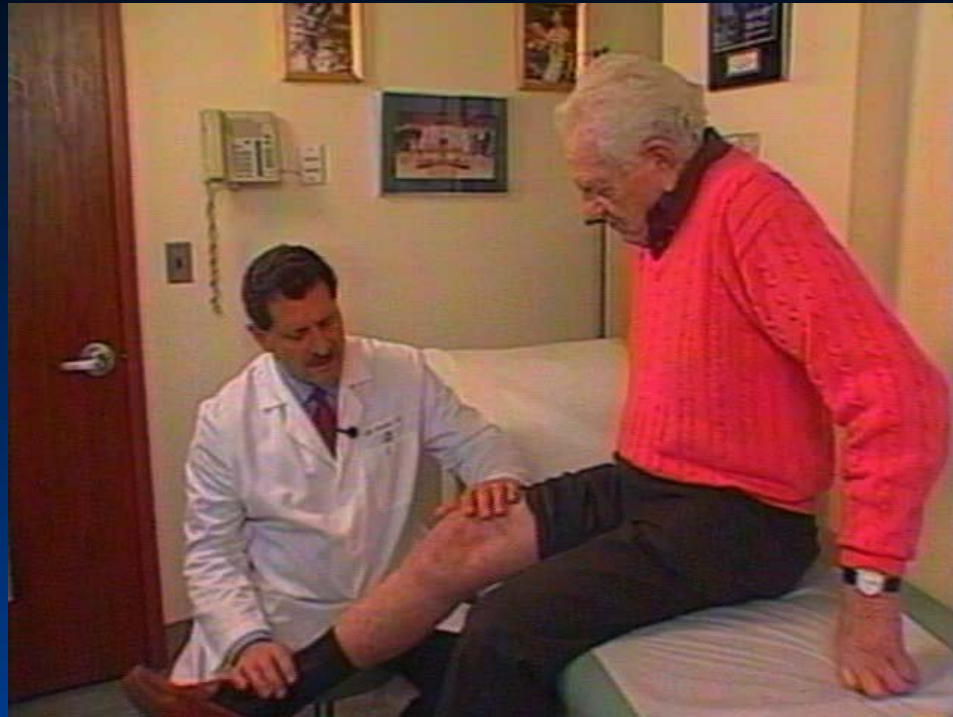- Gait pattern (antalgia)
- Spine, pelvic deformity
- Muscle atrophy
- Skin and prior incisions
- Alignment
 - Varus
 - Valgus
- Effusion




Physical Exam



- **Palpation**
 - Crepitus
 - Tenderness
 - Medial joint line
 - Lateral joint line
 - Peripatellar
 - Pes bursa
 - Pulses




Physical Exam



- **Motion**
 - Active motion
 - Passive ROM
 - Contractures
 - Fixed vs correctable deformities

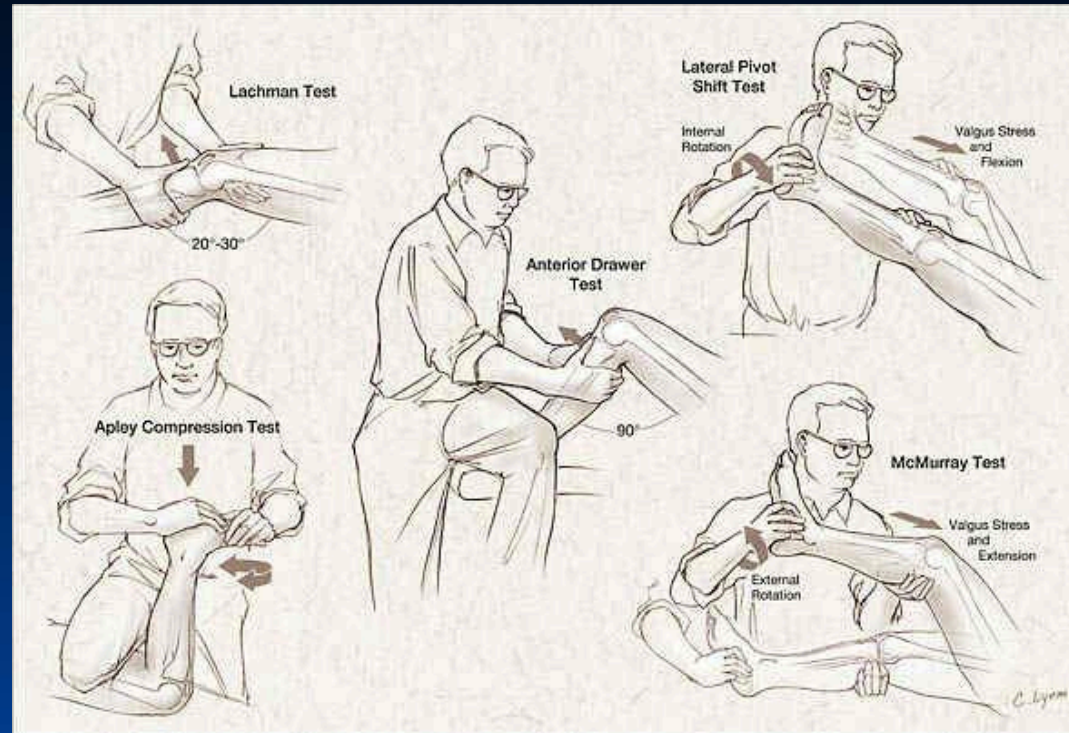


Physical Exam




- **Stability**

- Lachman
- Anterior drawer
- Posterior drawer
- Pivot shift
- Varus / valgus




Physical Exam



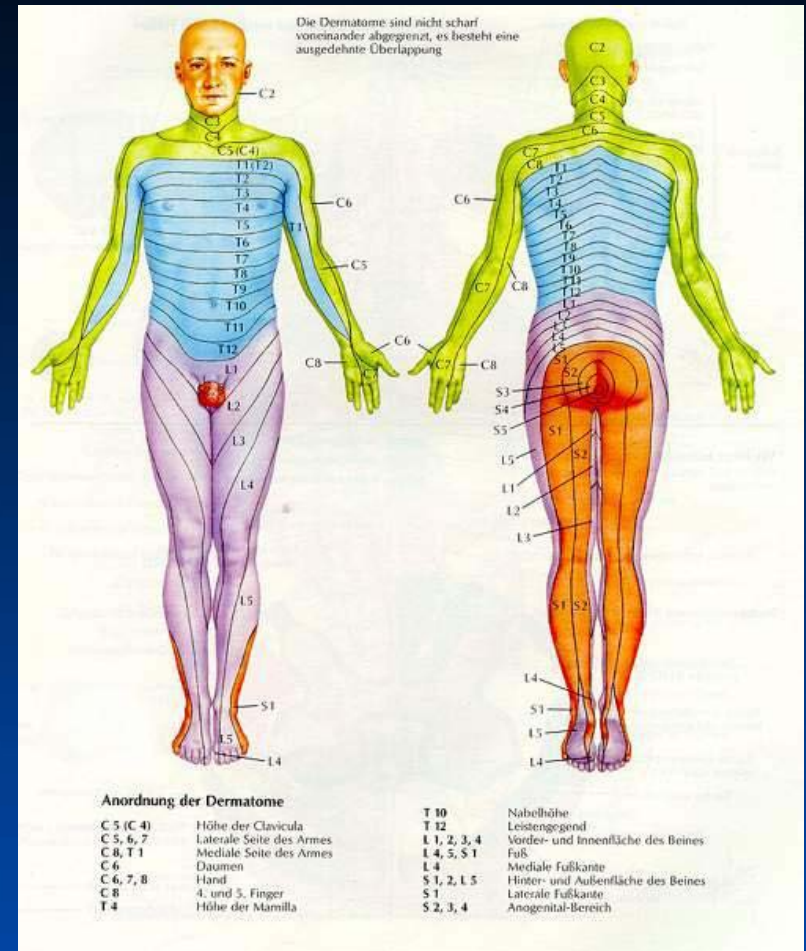
- **Strength**
 - Quadriceps
 - Extension lag?
 - Hamstrings




Physical Exam



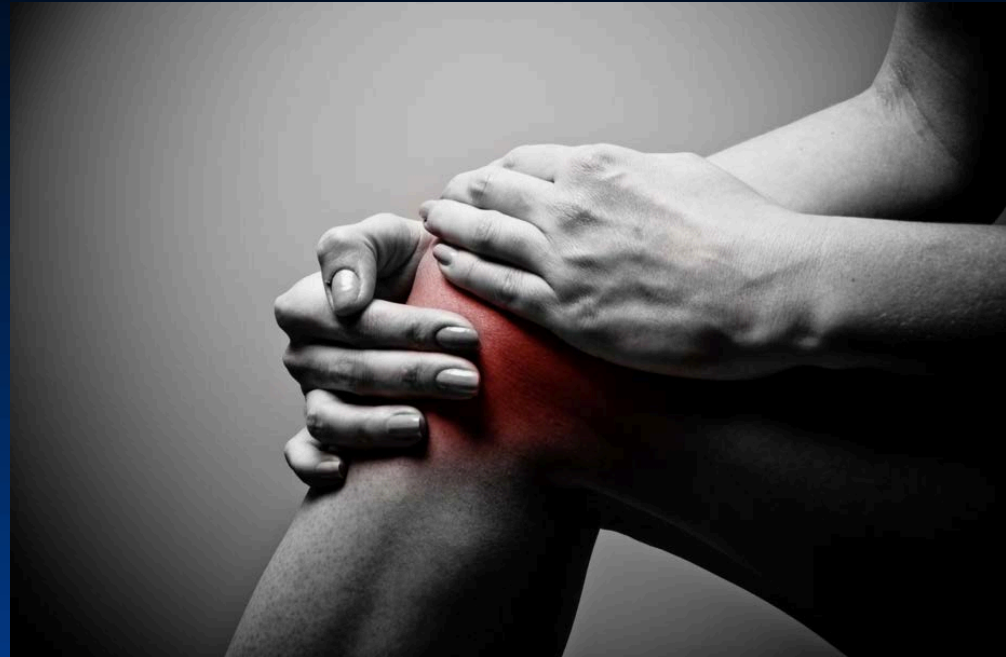- Neurologic exam




Differential Diagnosis



- **Extra-articular**
- **Peri-articular**
- **Intra-articular**



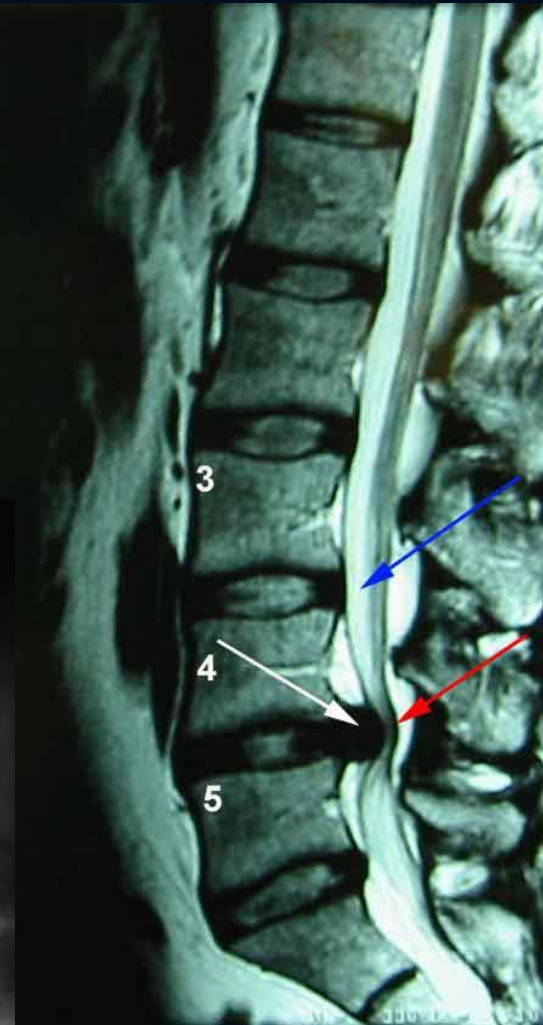
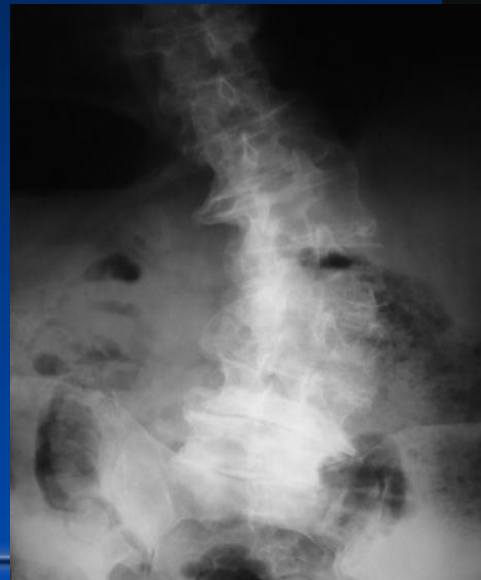
Differential Diagnosis




- **Extra-articular**

- Lumbar spine pathology

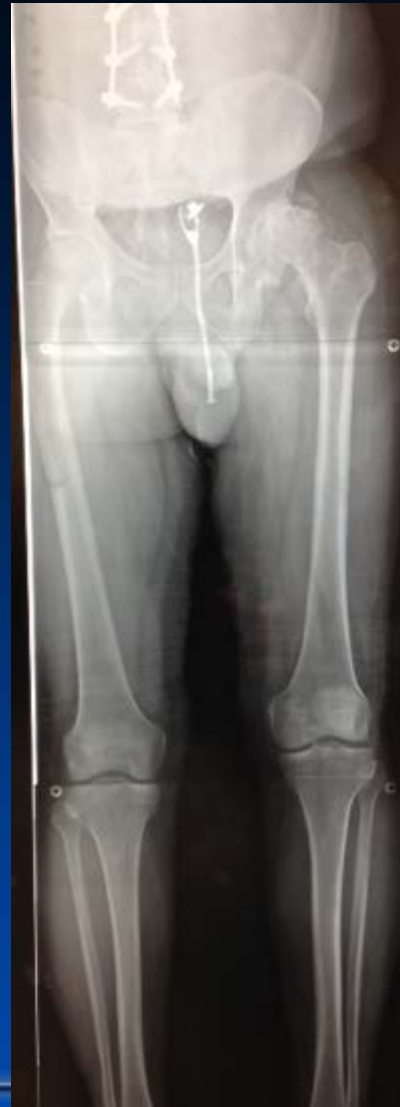- Degenerative disc disease
- Nerve root impingement
- Spinal stenosis




Differential Diagnosis



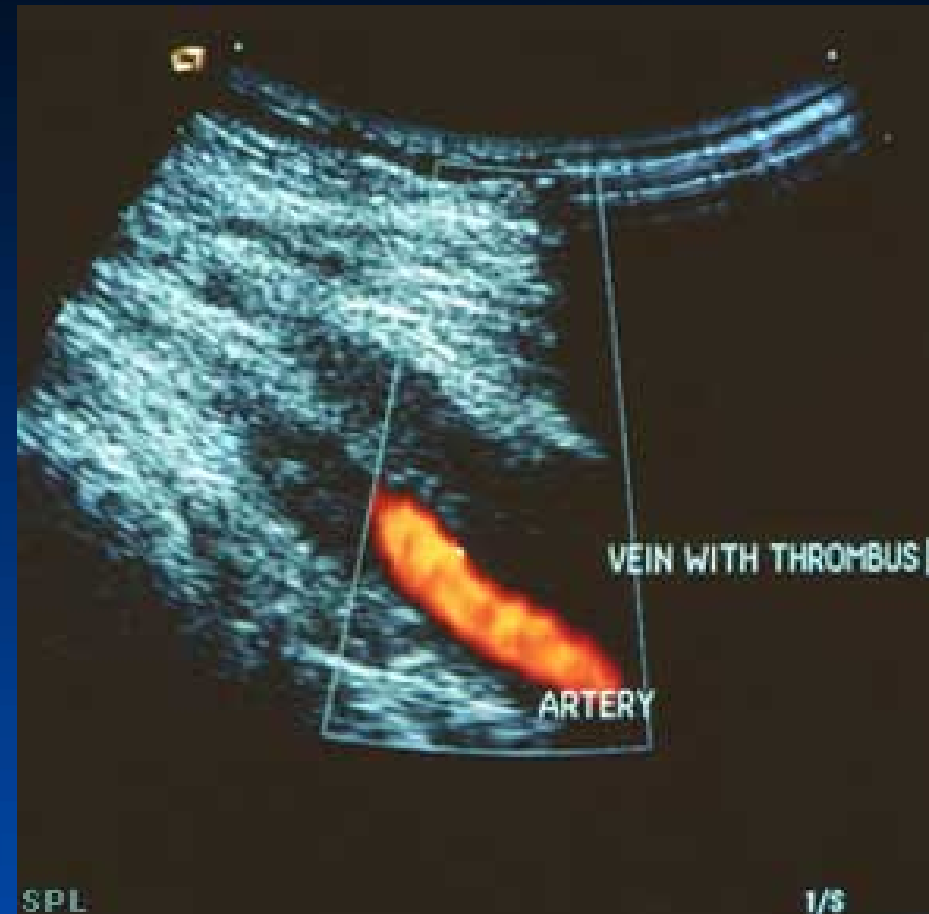- **Extra-articular**
 - Hip pathology
 - Arthritis
 - AVN
 - Fracture
 - Failed THA




Differential Diagnosis



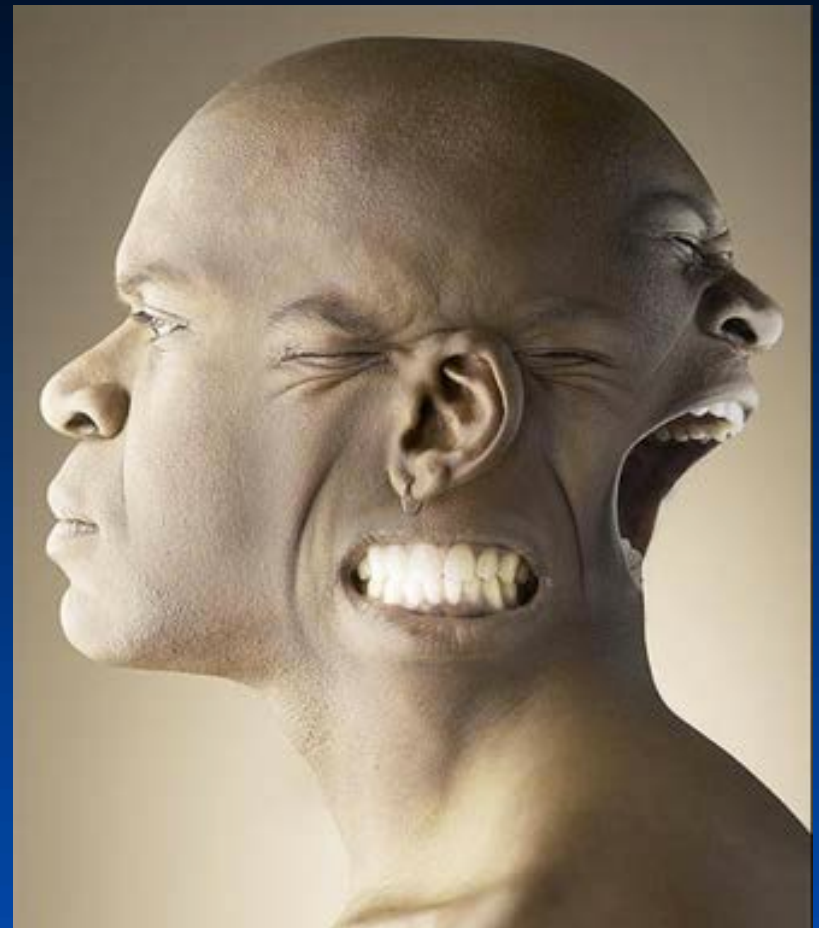
- **Extra-articular**
 - Vascular disease
 - Insufficiency
 - Aneurysm
 - Thrombosis




Differential Diagnosis



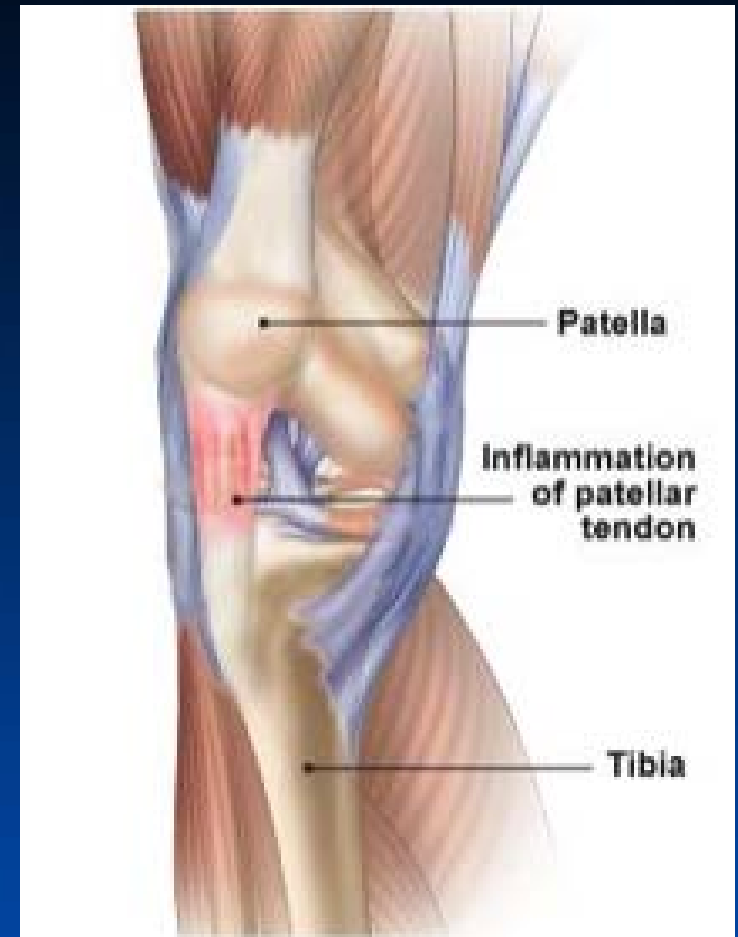- **Extra-articular**
 - Psychological illness




Differential Diagnosis



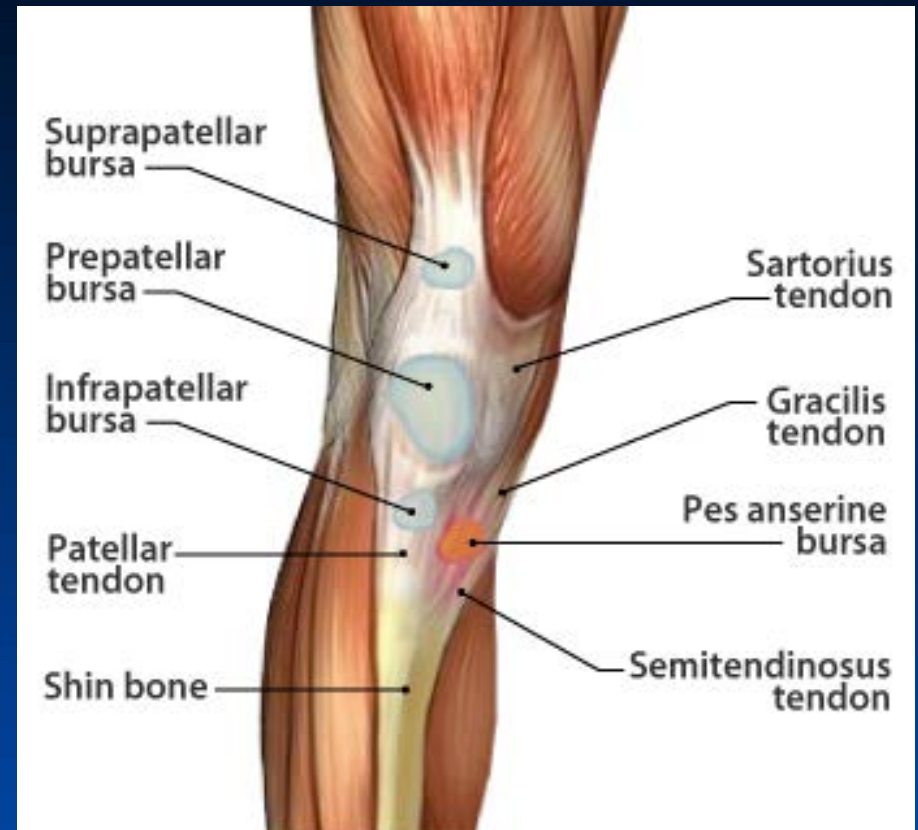- **Peri-articular**
 - Tendonitis
 - Patellar
 - Quadriceps
 - Hamstring
 - Iliotibial band




Differential Diagnosis



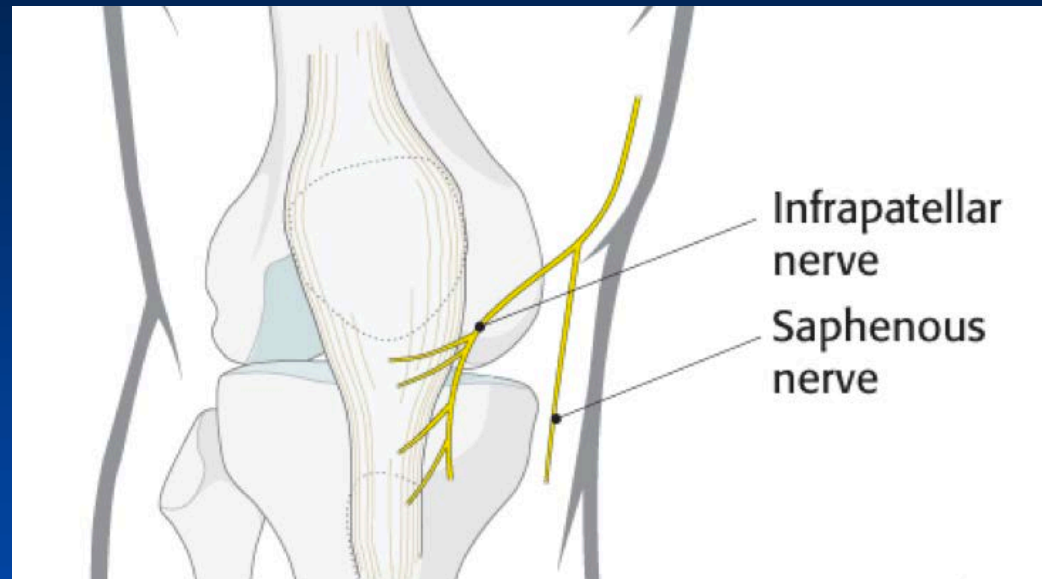
- Peri-articular
 - Bursitis
 - Prepatellar
 - Pes




Differential Diagnosis



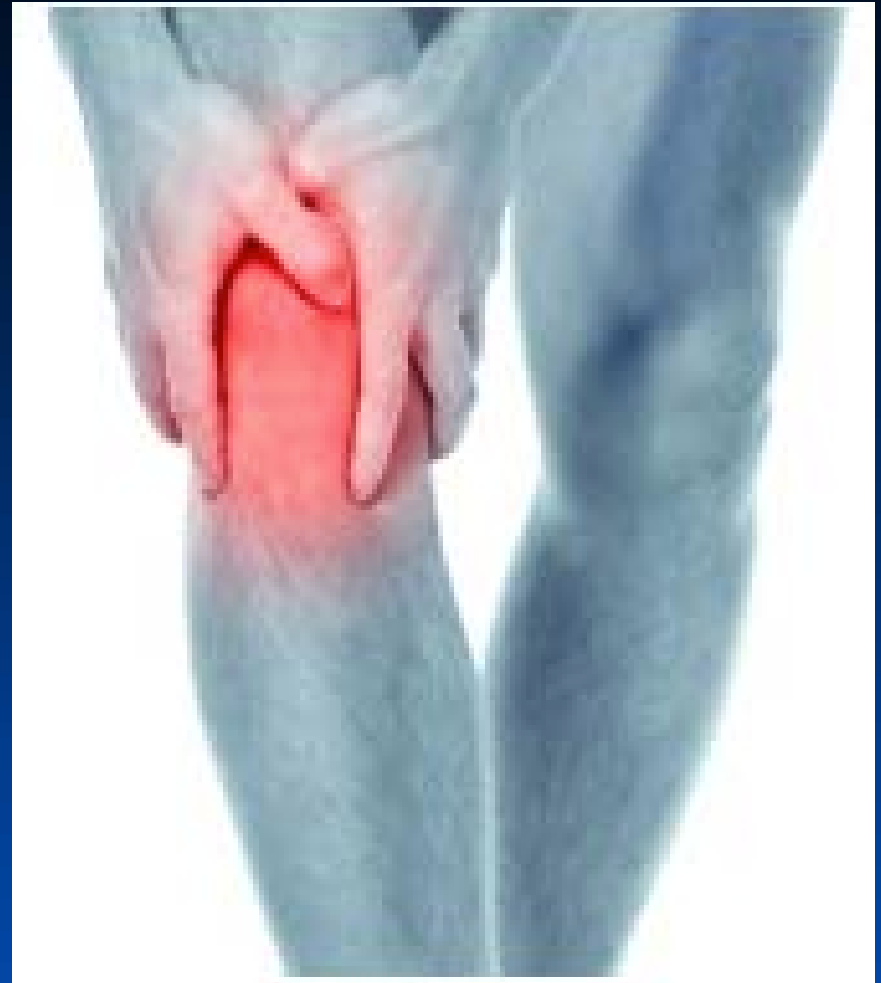- **Peri-articular**
 - Cutaneous neuroma
 - Saphenous neuralgia




Differential Diagnosis



- **Peri-articular**
 - Reflex sympathetic dystrophy




Differential Diagnosis




- **Intra-articular**
 - OA
 - Meniscal pathology
 - Ligament compromise
 - Osteochondritis dissecans
 - AVN
 - SPONK
 - Inflammatory arthropathy

Imaging Studies

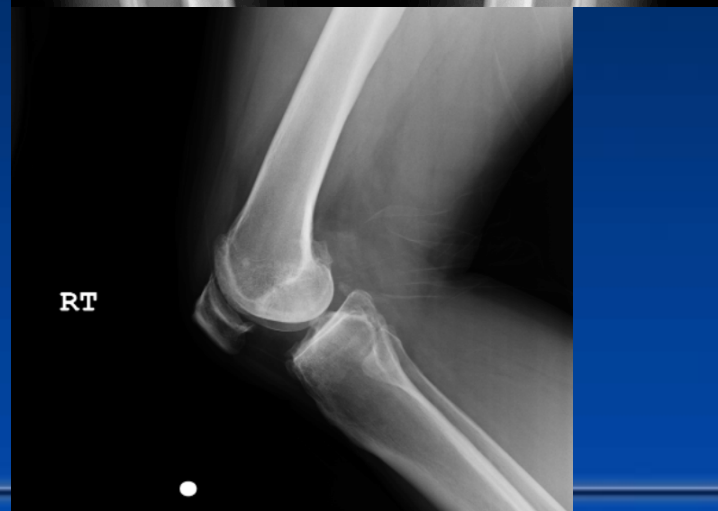
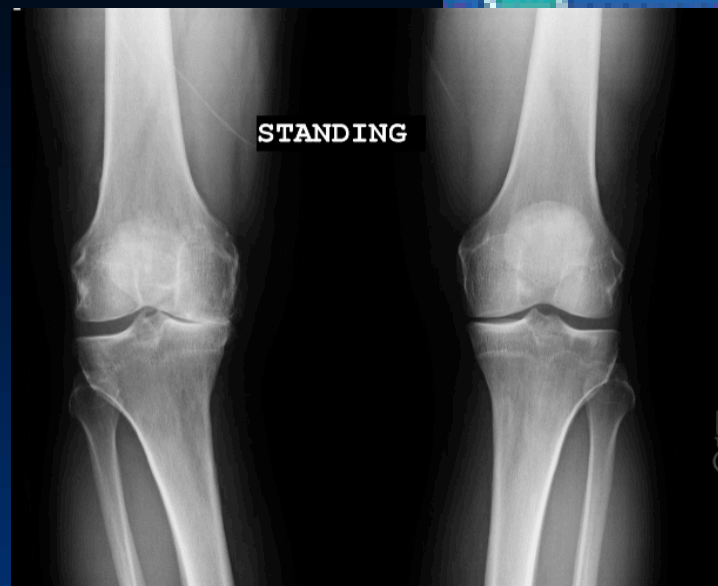
- **X-rays**
- **MRI**
- **CT scan**
- **Bone scan**


Radiographs



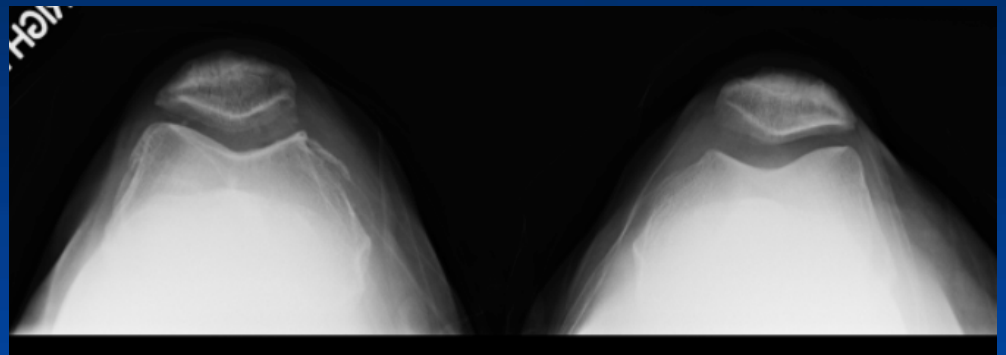
- **AP**
 - Weight-bearing
 - Fracture, joint space narrowing, OCD, loose bodies, alignment
- **Lateral**
 - Lateral decubitus with knee flexed 30 to 45 deg, tension on tendon
 - Patellar alta, baja
 - Patella fx




Radiographs



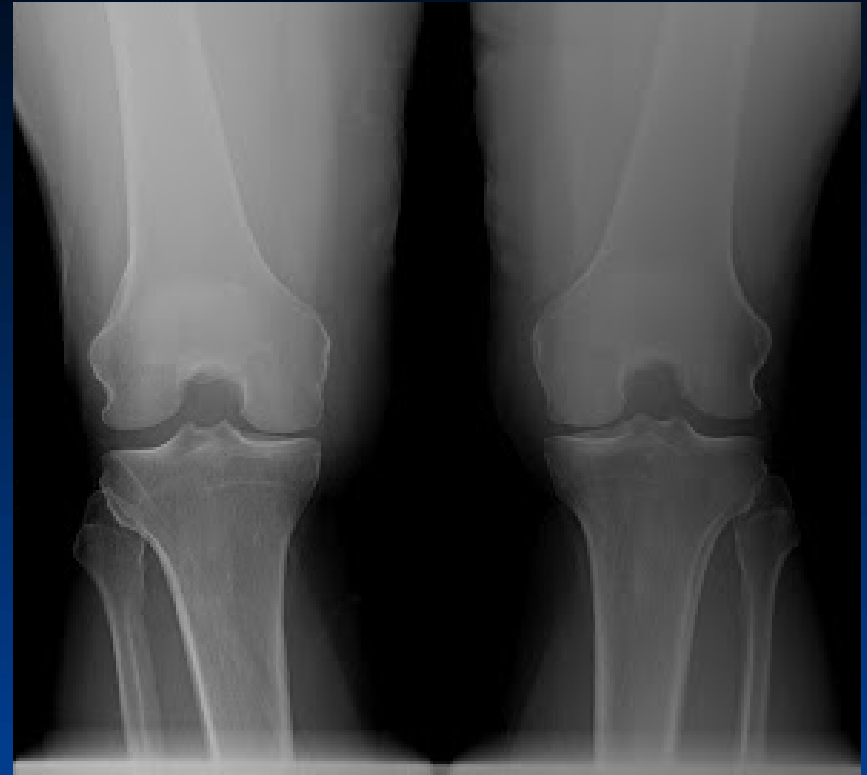- **Merchant**
 - Patellar tilt, subluxation, dislocation
 - Osteochondral fx
 - PF osteophytes



Additional Radiographs

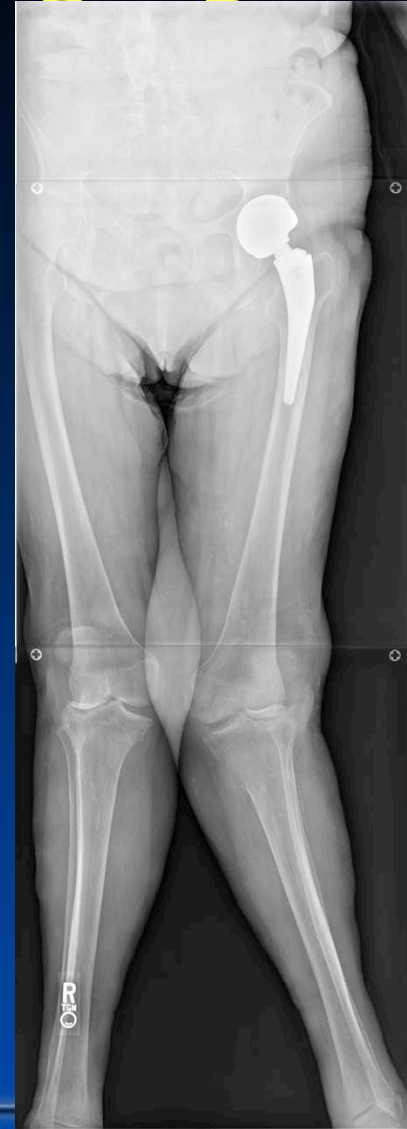


- **PA flexion (Rosenberg)**
 - Flexion WB radiograph
 - Assessment of early joint space narrowing
 - OCD



Additional Radiographs

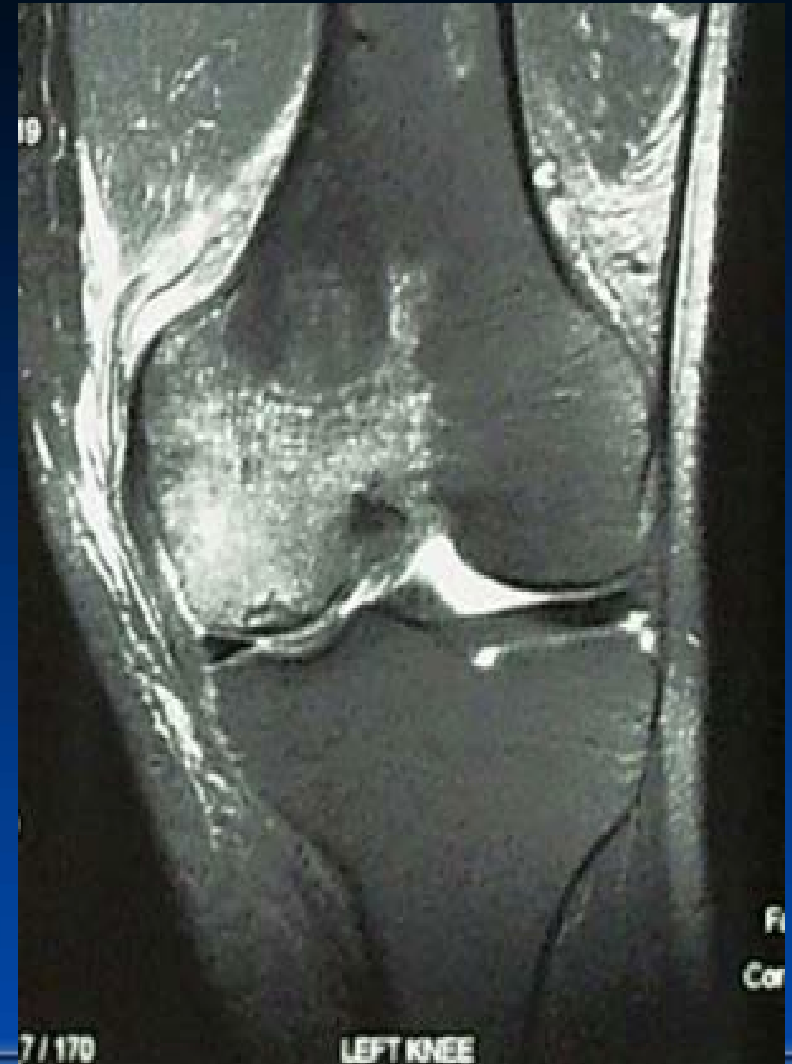- **Hip-to-ankle**
 - Limb alignment
 - Hip pathology
 - Pre-op templating




MRI



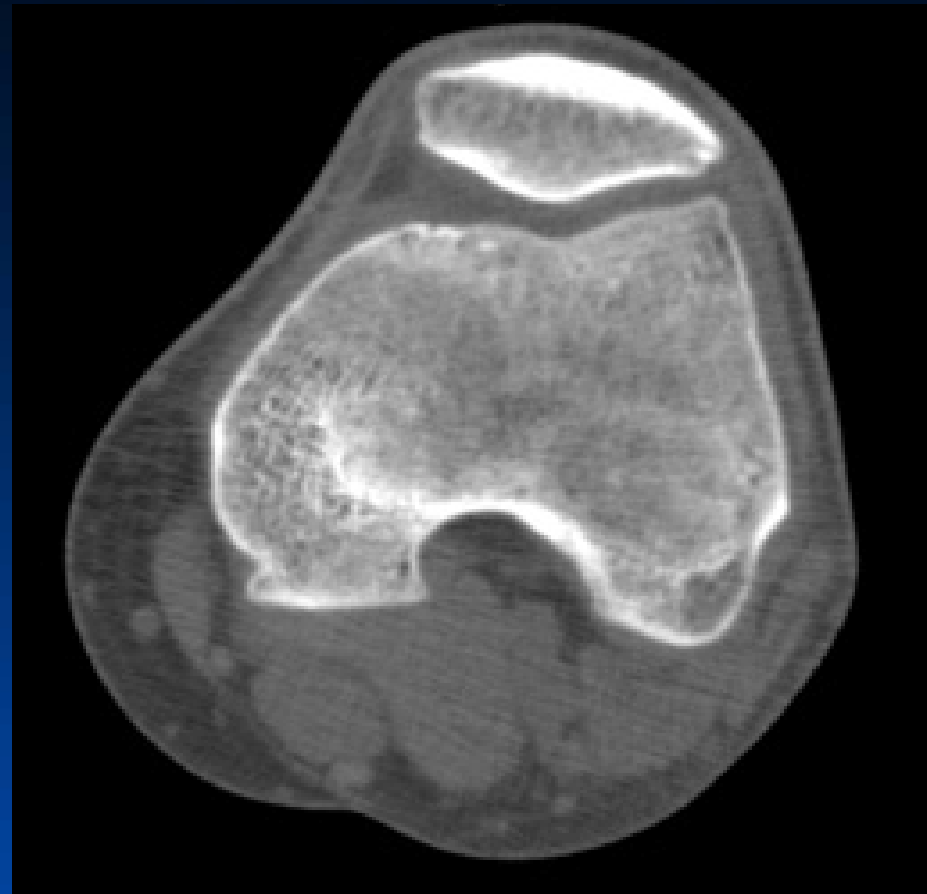
- Consider MRI when plain radiographs appear normal but need to further evaluate source of knee pain
- Reasonable for aiding in diagnosis of SPONK, AVN, meniscal tear, ligament tear




CT Scan



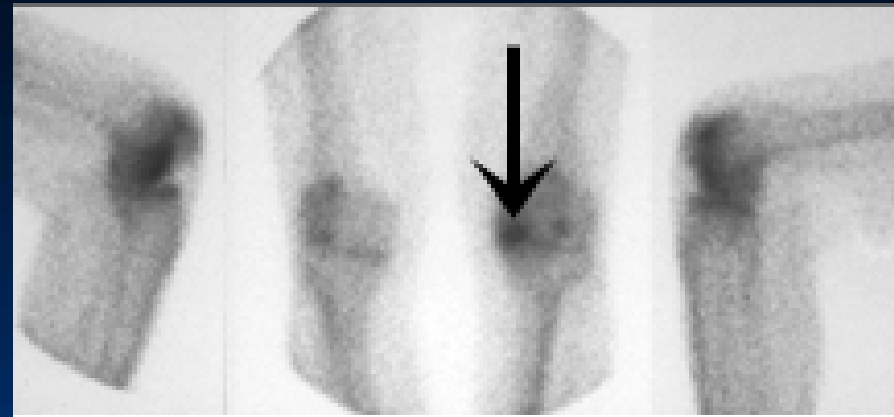
- **Fracture diagnosis**
 - Occult fracture
 - Fracture pattern
- **Patella-femoral malalignment**
- **Assess bone loss, defects**



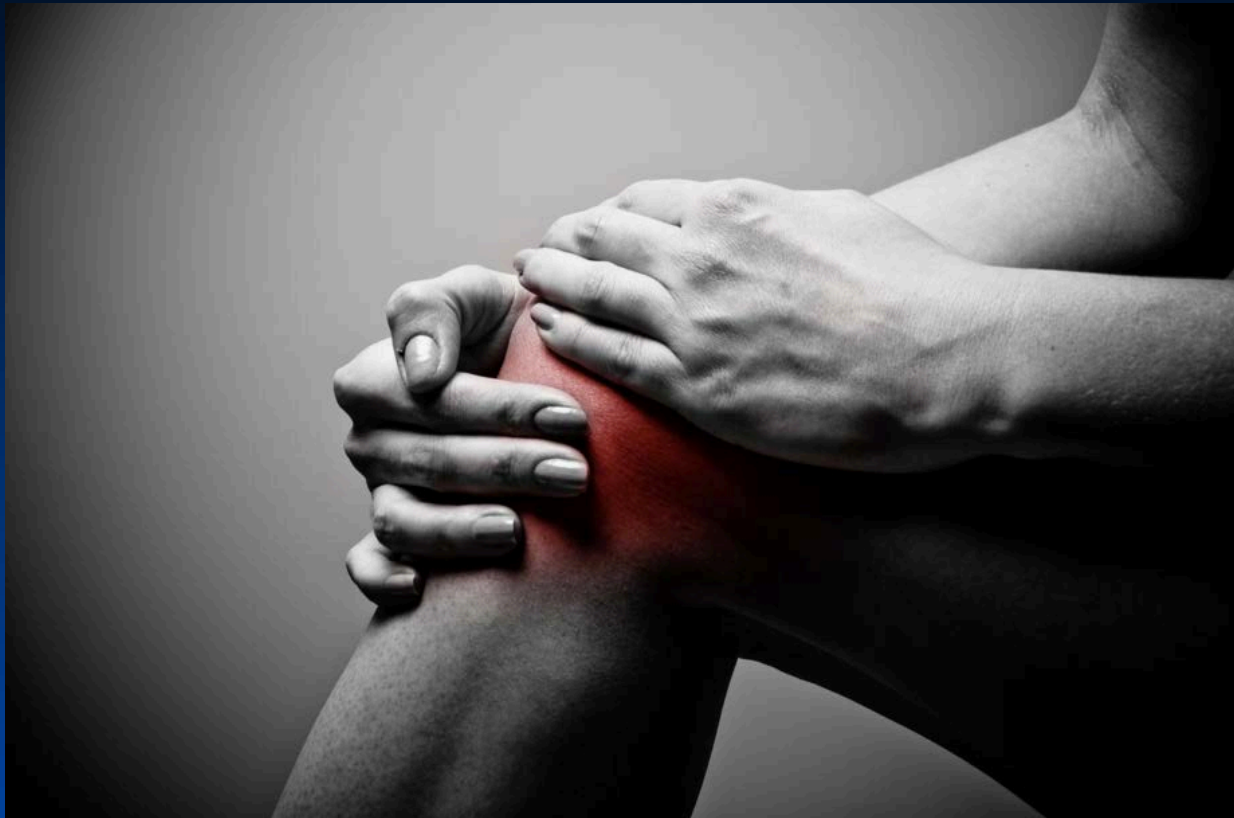
Bone Scan



- Technetium 99m
- Historically useful for diagnosis of SPONK
- Focally intense uptake of affected condyle or tibial plateau
- Less commonly utilized with the advent of MRI



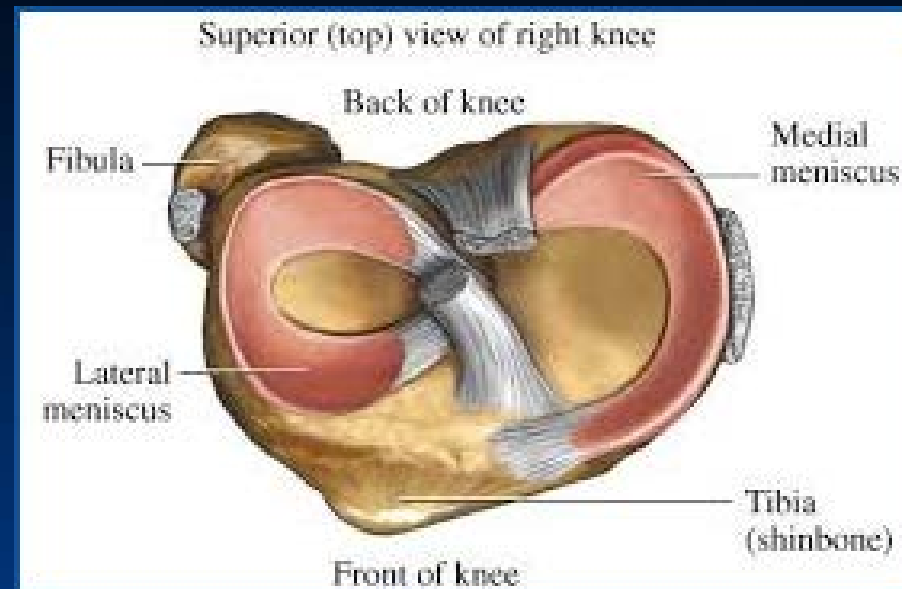
Specific Knee Conditions



Meniscus Tear



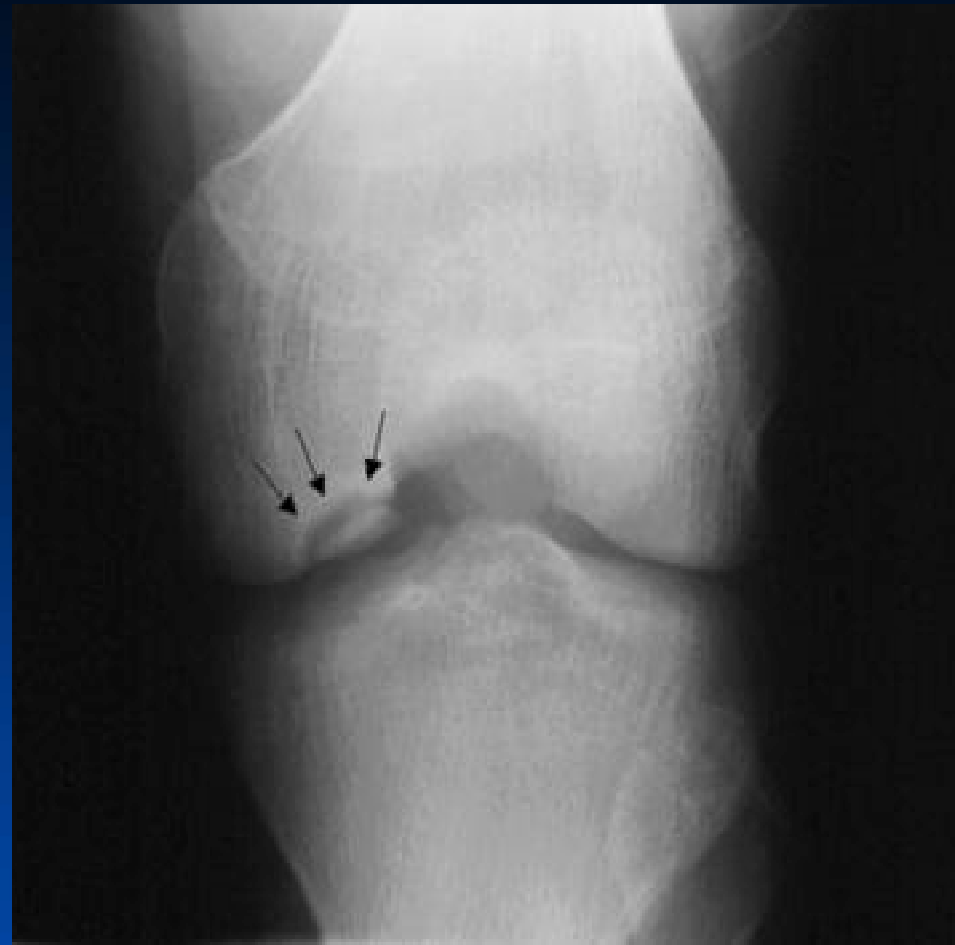- **Traumatic**
 - Twisting injury
 - Can be associated with ligament injury, hemarthrosis
- **Degenerative**
 - Usually complex tears
 - Locking, catching, giving way, effusions
 - Exacerbated by hyperflexion




Osteochondritis Dissecans



- More common in males
- Age 15 to 20
- MFC lateral aspect
- Gradual onset of symptoms
- 50% trauma hx
- Pain and locking if detached fragment




SPONK



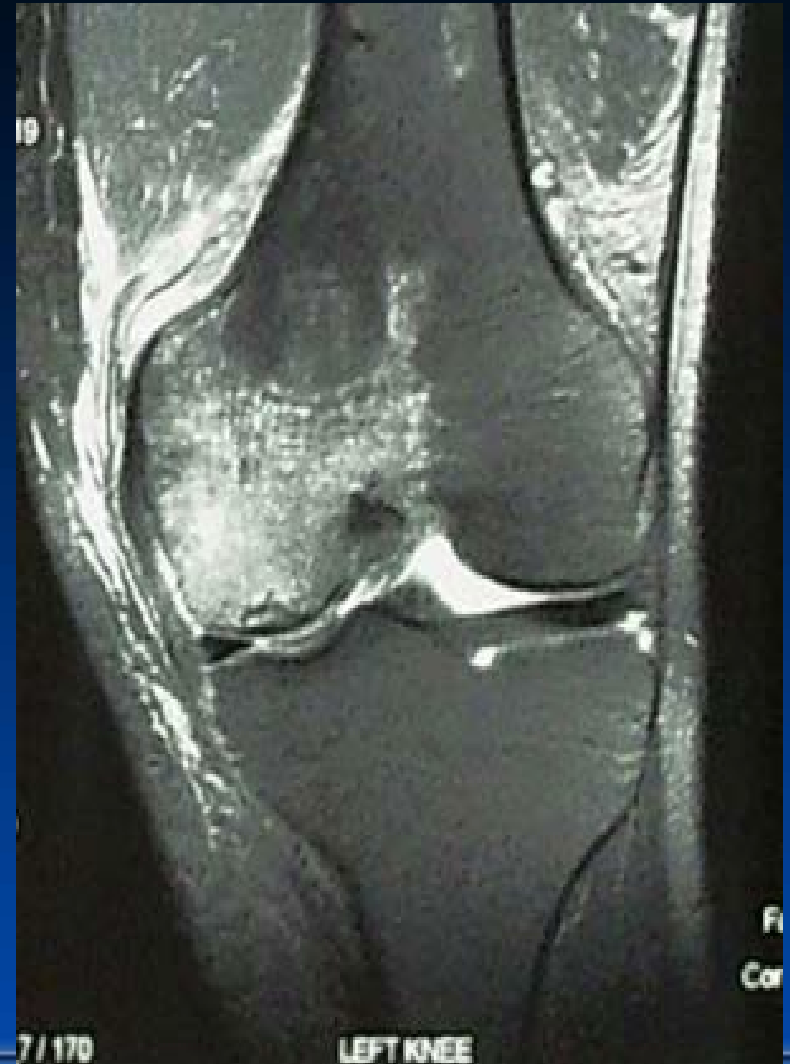- **3x more common in females**
- **Older than 60 yo**
- **Sudden onset of pain**
- **Worse at night**
- **Acute phase 6 to 8 wks**




SPONK



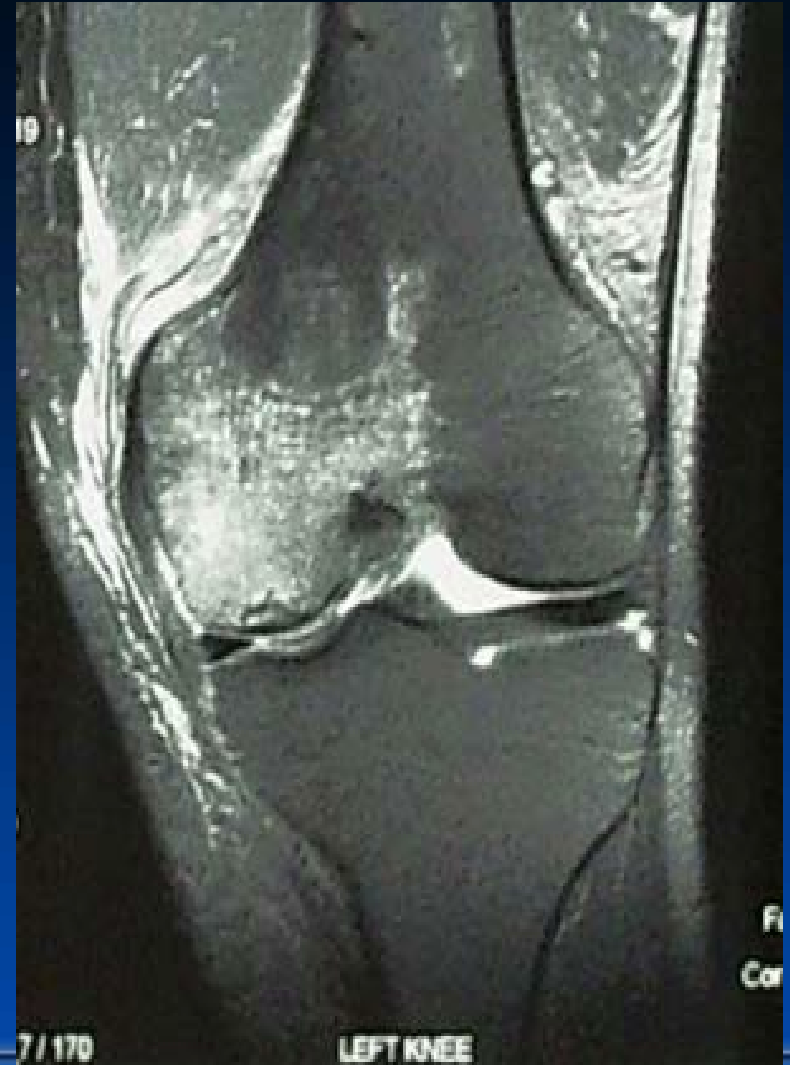- Focal area of severe tenderness on medial femoral condyle
- May appear locked due to pain, effusion, muscle spasm
- Usually medial fem condyle but can also be lateral fem condyle, tib plateau




SPONK



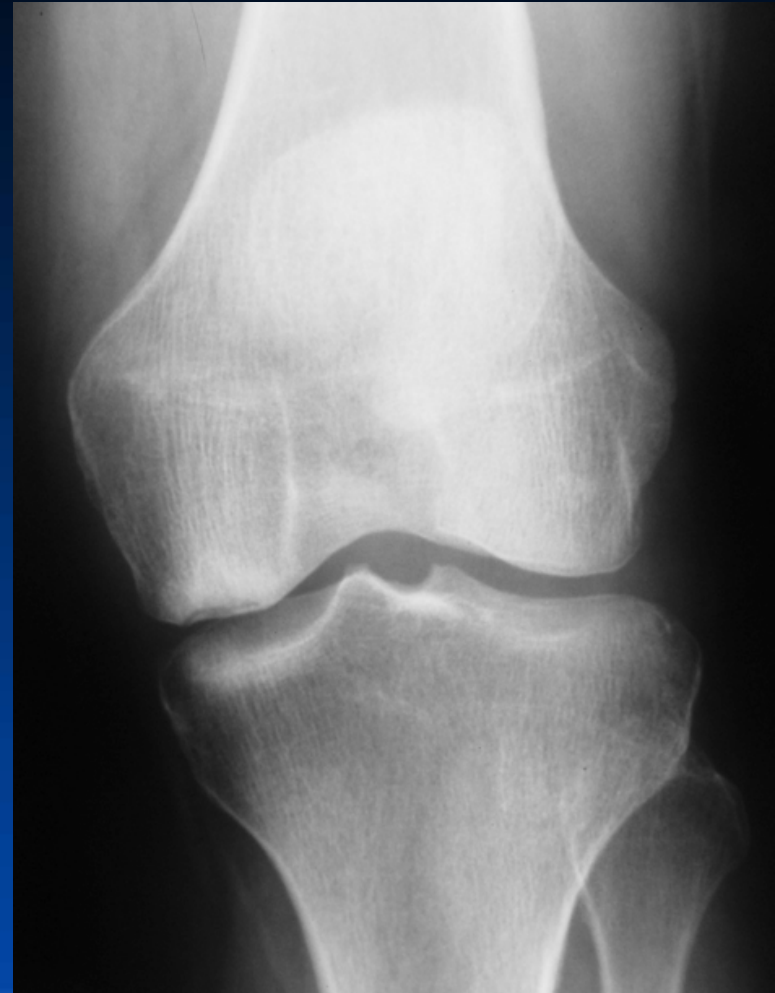- Stage 1 – normal x-rays, positive bone scan, bone edema on MRI T2



SPONK



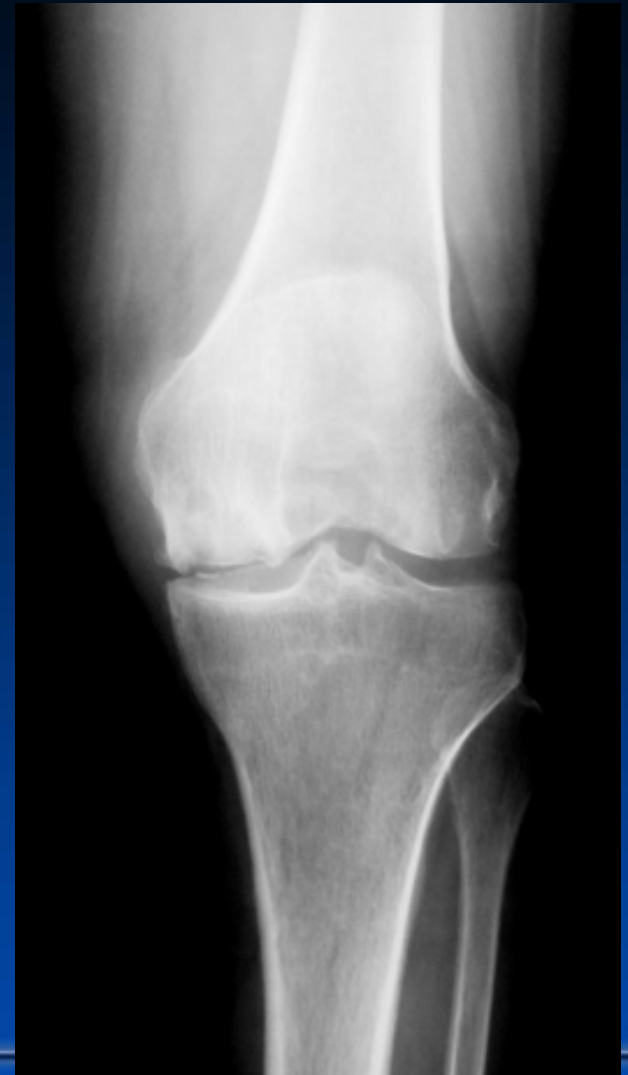- **Stage 2 – flattening of weight-bearing portion**
- **Stage 3 – radiolucent area, sclerotic halo**




SPONK



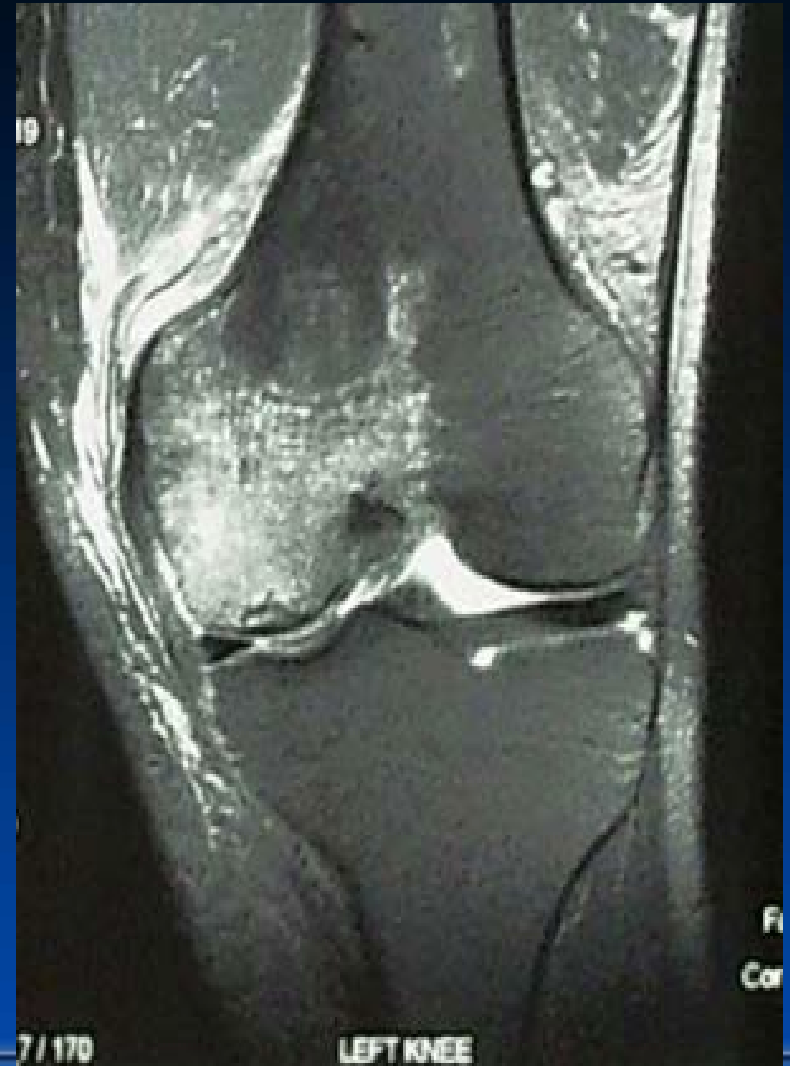- **Stage 4 – subchondral collapse**
- **Stage 5 – bony collapse with secondary degeneration**




SPONK



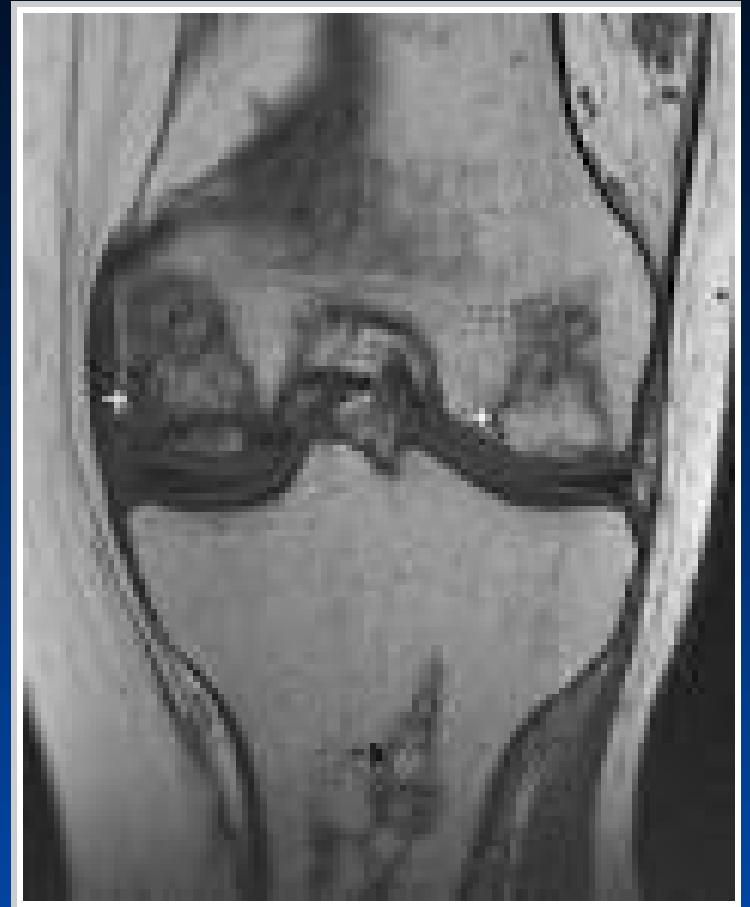- **Non-op rx**
 - Crutches, NSAIDS, PT
 - **Good results with symptomatic rx**
- **Operative**
 - Scope debridement
 - Osteochondral allograft
 - HTO
 - Core decompression
 - Arthroplasty




Secondary Osteonecrosis



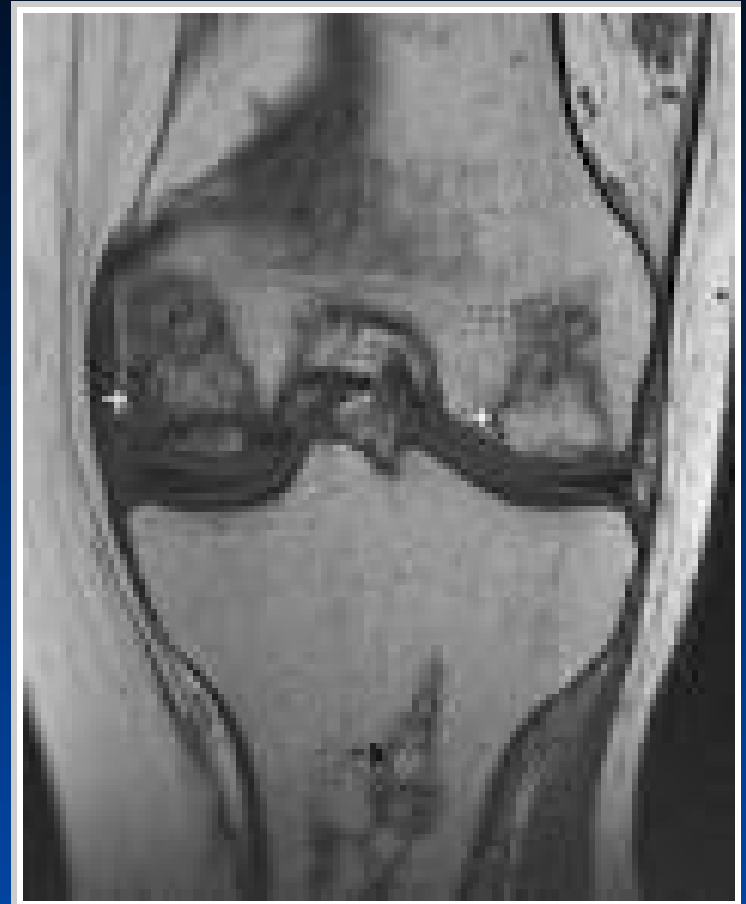- Younger than 45 yo
- Gradual onset of pain
- > 80% bilateral
- Multiple lesions
- Often have concomitant hip involvement
- Steroids, EtOH, SLE, sickle cell anemia, Gaucher's, caisson




Secondary Osteonecrosis



- **Non-op rx**
 - Crutches, NSAIDS, PT
 - POOR results with conservative rx
- **Operative**
 - Scope debridement
 - Osteochondral allograft
 - HTO
 - **Core decompression**
 - **Arthroplasty**

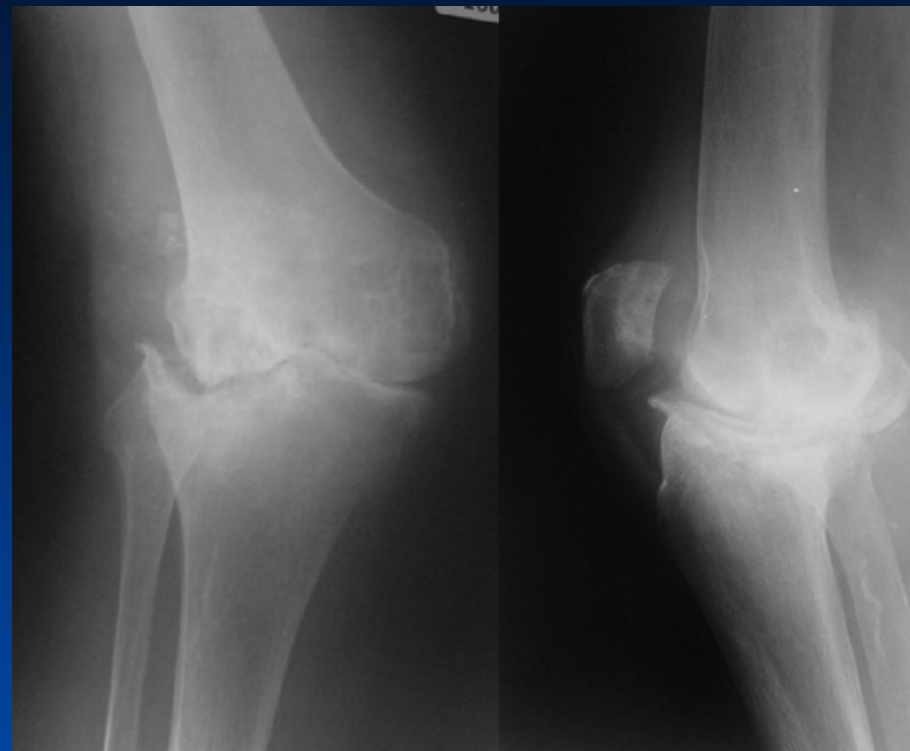


Inflammatory Arthritis



- **Systemic conditions**

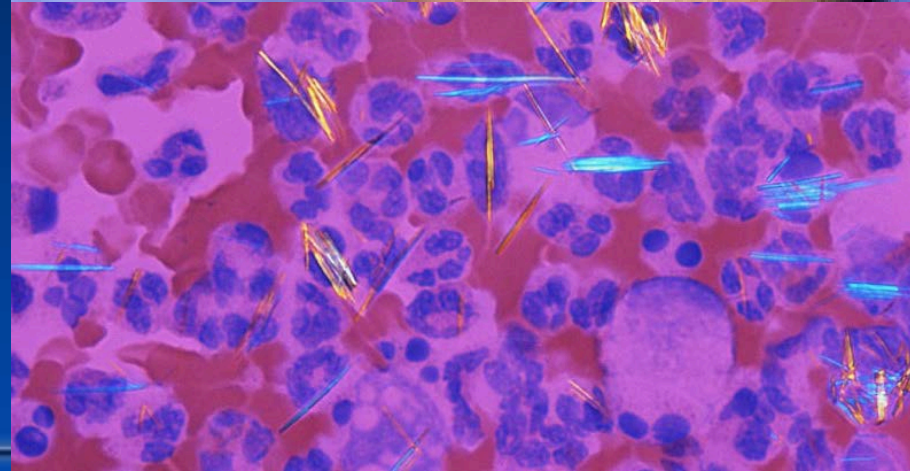
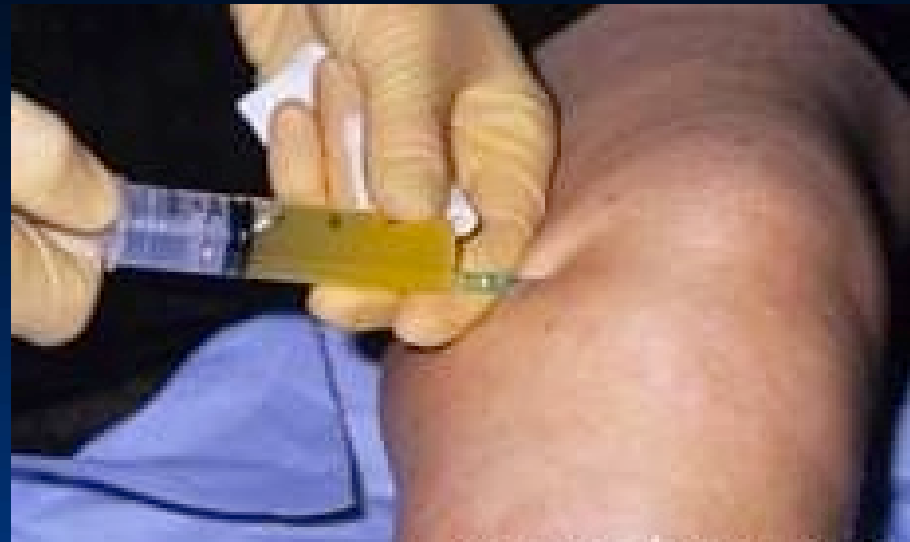- Rheumatoid arthritis
- Psoriatic arthritis
- Reactive arthritis
- Colitis-associated arthritis
- Undifferentiated spondyloarthropathy
- Lupus
- Sarcoidosis
- Behcet's disease




Inflammatory Arthritis



- **Crystal-associated**
 - Gout
 - Calcium pyrophosphate disease
 - Calcium oxalate disease




Arthrocentesis

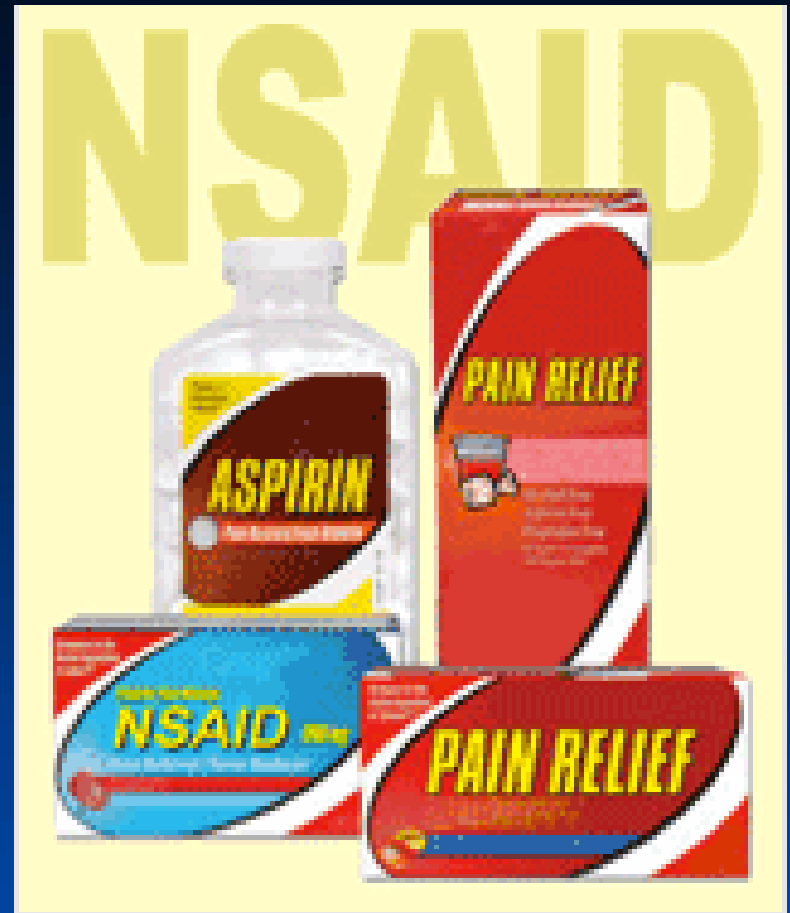

- **Inflammatory**
- **WBC 2000 - 75,000**
- **PMN > 50%**
- **Crystals - present?**
- **Culture - negative**
- **Septic**
- **WBC > 100,000**
- **PMN > 75%**
- **Crystals - none**
- **Culture - positive**


Inflammatory Arthritis



- **Treatment**
 - NSAIDs
 - COX-2 selective inhibitors
 - Corticosteroids



Inflammatory Arthritis



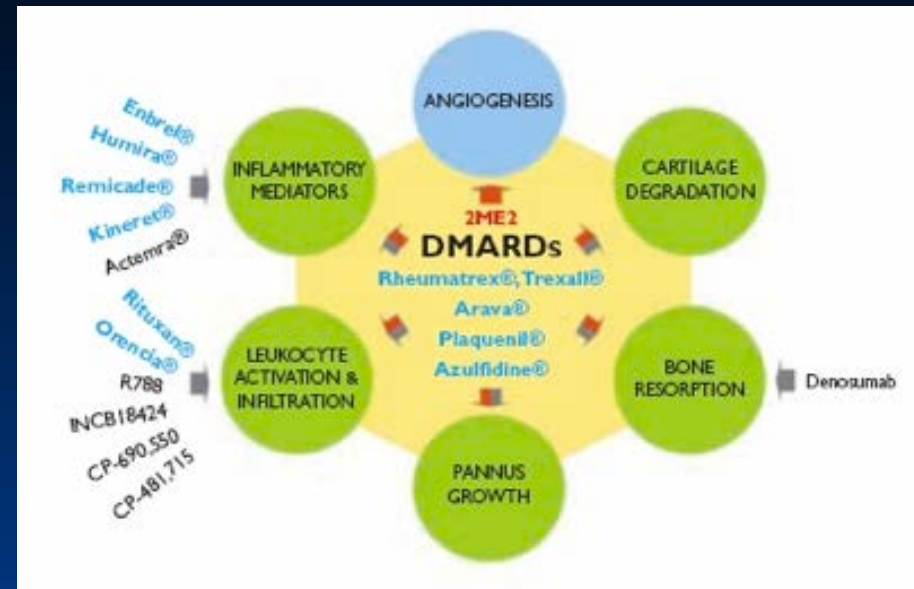
- **Treatment**

- Disease-Modifying Anti-rheumatic Drugs

- Hydroxychloroquine, sulfasalazine, methotrexate, leflunomide, etanercept, infliximab, akakinra, adallimumab

- Biological Response Modifiers

- TNF α antagonist
 - IL-1 antagonist





Summary



- **A thorough history, physical exam, and plain x-rays can establish diagnosis in most cases**
- **Differential diagnosis should include extra-articular, peri-articular, and intra-articular etiologies**
- **Ancillary testing / imaging may be helpful in equivocal cases**

Thanks for your attention



**Colorado Joint Replacement
Porter Adventist Hospital
Denver, Colorado**
